


VLESPOTLIGHT

NvisionVLE® Imaging System



CASE STUDY: VLE for Surveillance

PATIENT HISTORY

This patient was a 69 year old man with long segment (Prague Criteria C10M10) Barrett's Esophagus (BE) with high grade dysplasia (HGD). Initial endoscopic mucosal resection (EMR) specimens were negative for dysplasia. For this procedure, a surveillance endoscopy was performed to localize abnormalities using the NvisionVLE® Imaging System.

Dr. Stuart R. Gordon, MD

Director, Gastrointestinal Endoscopy
Associate Professor of Medicine
Dartmouth-Hitchcock Medical Center
Lebanon, NH

PROCEDURE

ENDOSCOPIC EXAM

The esophagogastroduodenoscopy (EGD) showed a long segment of BE. White light endoscopy (WLE) and narrow band imaging (NBI) revealed no suspicious lesions (Fig. 1).

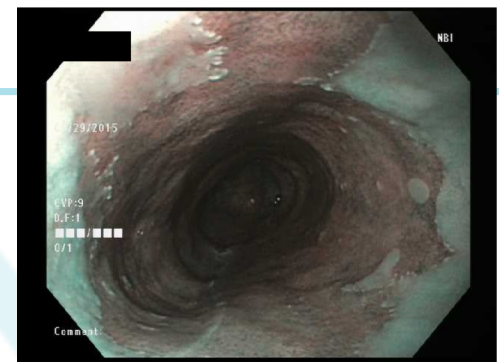
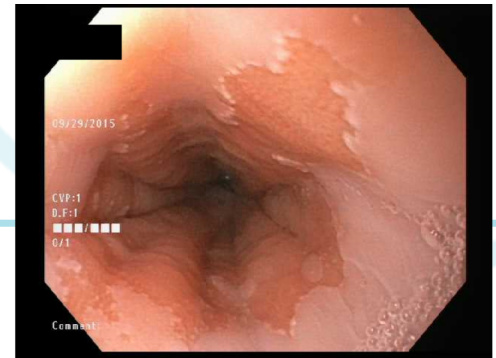

Figure 1: White light endoscopy (top) and narrow band imaging (bottom) of the proximal region of BE

VLE

Volumetric Laser Endomicroscopy

The BE region was imaged using the NvisionVLE® Imaging System. Just proximal to the gastroesophageal junction (GEJ), VLE identified a large cluster of atypical glands adjacent to the previous EMR site (Fig. 2). EMR was performed at the site of VLE findings, and further *in vivo* VLE showed no residual atypical glands post-EMR.

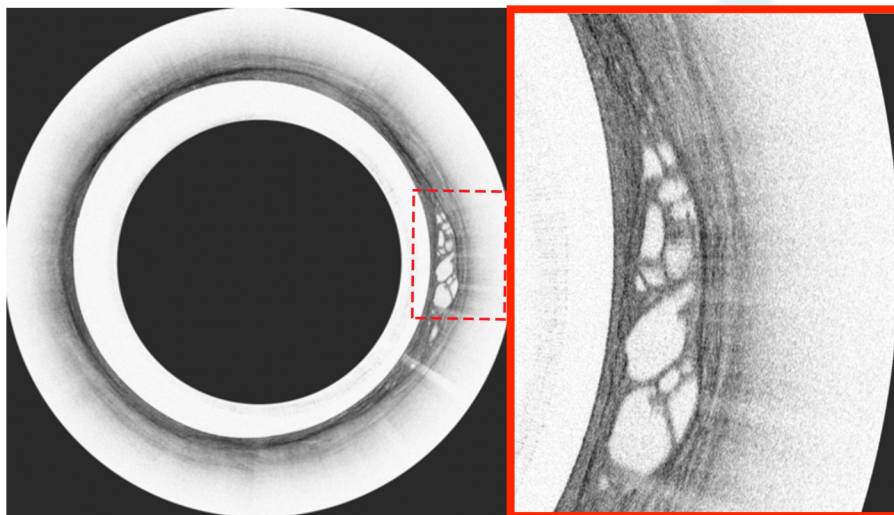


Figure 2: NvisionVLE® Scan data adjacent to the GEJ. Transverse scan (left) shows an area of concern (highlighted, right).

RESULTS

Pathology confirmed HGD bordering on intramucosal carcinoma in a background of BE with negative margins.

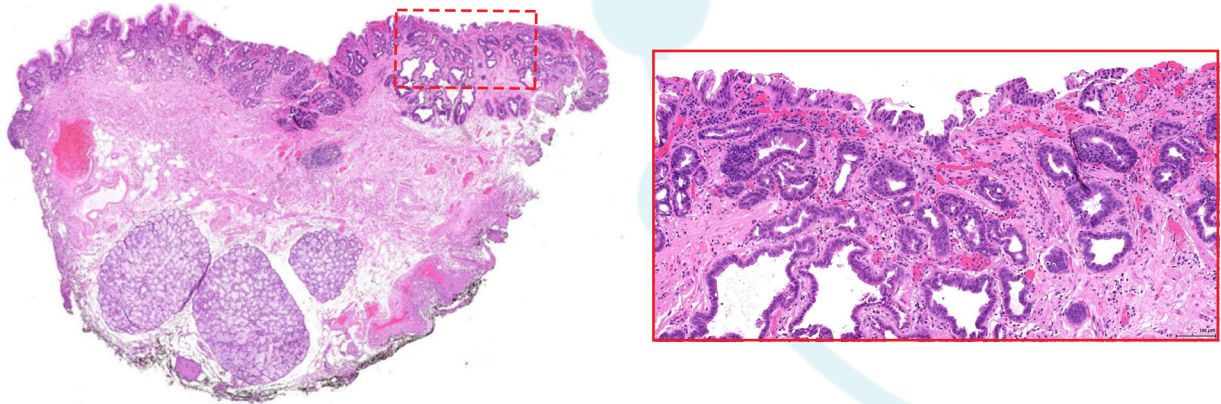


Figure 3: Low power pathology image from EMR specimen (left). High power pathology image from EMR specimen (right). Pathology confirmed HGD bordering on intramucosal carcinoma in the VLE-guided tissue resection.

DISCUSSION

The intent of this procedure was to identify areas of HGD as part of BE surveillance protocol with **no suspicious lesions identified using WLE or NBI**. Using the NvisionVLE® Imaging System, clear sub-surface abnormalities were identified proximal to the GEJ, and regions for endoscopic resection were defined. The mucosal changes that included a large cluster of atypical glands were sampled and confirmed by pathology as HGD bordering on intramucosal carcinoma with negative margins. Although continued studies will be required to prove the broader impact of Advanced OCT in the management of Barrett's related dysplasia, its impact on this particular patient and their treatment is undeniable.



12 Oak Park Drive
Bedford, MA 01730

Main Office 617-250-7190
www.ninepointmedical.com

For More Information:
info@ninepointmedical.com

The NvisionVLE® Imaging System is indicated for use as an imaging tool in the evaluation of human tissue microstructure, including esophageal tissue microstructure, by providing two-dimensional, cross-sectional, real-time depth visualization, and may be used to mark areas of tissue. The safety and effectiveness of this device for diagnostic analysis (i.e. differentiating normal versus specific abnormalities) in any tissue microstructure or specific disease has not been evaluated.

900218 rev. A